

Case Report

Focused Ultrasound Assists in Diagnosis and Management of Difficult Airway in Ludwig's Angina

CME
Credits

Chang-Chih Shih¹, Jen-Chun Wang¹, Sy-Jou Chen¹, Yuan-Pin Hsu^{2,3,4*}

¹Department of Emergency Medicine, National Defense Medical Center, Tri-Service General Hospital, Taipei, Taiwan, ²Department of Emergency, Wan Fang Hospital, Taipei Medical University, Taipei, Taiwan, ³Graduate Institute of Clinical Medicine, College of Medicine, Taipei Medical University, Taipei, Taiwan, ⁴Department of Emergency, School of Medicine, College of Medicine, Taipei Medical University, Taipei, Taiwan

Abstract

Ludwig's angina is a rapidly progressive and life-threatening medical emergency. The mortality rate is about 8%. Management of the difficult airway in Ludwig's angina has been challenging for clinical physicians. We reported an otherwise healthy 49-year-old female, who visited our emergency department with progressive swelling of her chin, drooling, and dyspnea. Ludwig's angina with impending airway compromise was promptly identified. The precise anatomy of the distorted neck was accessed using ultrasound as an adjunct. Emergent tracheostomy was then established successfully within minutes. Physicians should consider using ultrasound as an adjunct to define anatomy before performing emergent surgical airways.

Keywords: Airway management, focused ultrasound, Ludwig's angina

INTRODUCTION

Ludwig's angina is one of the severe soft-tissue infections of the head and neck, which is characterized by oral pain, difficulty swallowing and managing oral secretions, elevation of the tongue, and trismus. Ludwig's angina is a potentially fatal infection with a mortality rate of around 8%.^[1] Rapidly progressing upper airway obstruction with asphyxiation is hazardous and can be fatal. Timely and appropriate management of emergency airway is essential. Focused ultrasound is a tool, which helps clinicians or surgeons to assess the anatomy and manage the emergent airway in the emergency department.^[2] Here, we reported a case with Ludwig's angina that was complicated with laryngospasm while trying to intubate with fiberscope assistance. The patient received predefined airway assessment by focus ultrasound, which assisted the surgeon to identify the anatomy and facilitate airway management more quickly and adequately.

CASE REPORT

An otherwise healthy 49-year-old female presented to our emergency department with a 3-day history of intermittent fever,

odynophagia, progressive swelling of her chin, drooling, and dyspnea. On arrival, her body temperature was 39.0°C, blood pressure was 158/98 mmHg, pulse rate was 125 beats/min, respiration rate was 24 breaths/min, and SpO₂ 96% on room air. Physical examination revealed erythematous change with heat over her chin, a swollen floor of mouth with a decreased interincisal distance, and distorted anatomy of her neck. Laboratory examination disclosed white blood cell count of 19100/μl, serum creatinine of 0.7 mg/dl, lactic acid of 5.7 mmol/L, and procalcitonin of 58.89 ng/ml. We applied focused ultrasound (Philips L12-3 broadband linear array transducer with a frequency range of 3–12 MHz) examination for her, which disclosed cobblestone appearances over submandibular, submental region, and pretracheal region compatible with Ludwig's angina. Meanwhile, we identified the precise position of trachea without overt abscess formation [Figure 1a and b]. Subsequent computed tomography of the neck and upper thorax showed diffuse soft-tissue swelling of the sublingual, submental,

Address for correspondence: Dr. Yuan-Pin Hsu,

Department of Emergency, Wan Fang Hospital, Taipei Medical University,
No. 111, Sec. 3, Xinglong Road, Wenshan District, Taipei City 116, Taiwan.
E-mail: koakoahsu@gmail.com

Received: 26-09-2018 Accepted: 31-10-2018 Available Online: 08-01-2019

Access this article online

Quick Response Code:



Website:
www.jmuonline.org

DOI:
10.4103/JMU.JMU_95_18

This is an open access journal, and articles are distributed under the terms of the Creative Commons Attribution-NonCommercial-ShareAlike 4.0 License, which allows others to remix, tweak, and build upon the work non-commercially, as long as appropriate credit is given and the new creations are licensed under the identical terms.

For reprints contact: reprints@medknow.com

How to cite this article: Shih CC, Wang JC, Chen SJ, Hsu YP. Focused ultrasound assists in diagnosis and management of difficult airway in Ludwig's angina. J Med Ultrasound 2019;27:101-3.

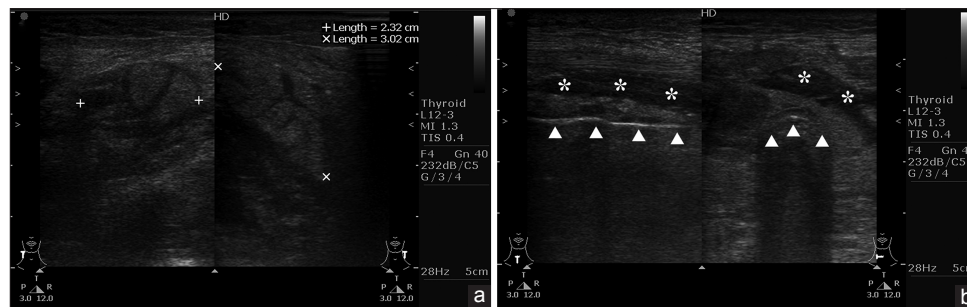


Figure 1: Focused ultrasound showed (a) cobblestone over the submandibular and submental region (cursors) and (b) subcutaneous edema filling the interlobar septae rather than abscess formation (asterisks) and the exact position of the tracheal ring (arrowheads)

and submandibular areas accompanied with upper elevation of the tongue and consequently caused upper airway pending obstruction [Figure 2a and b]. We adopted a strategy of awake fiberoptic endotracheal intubation with tracheostomy standby as a backup. Unfortunately, the patient developed sudden cyanosis, bradycardia, and declined consciousness with difficulty in further bag ventilation while attempting to intubation, which was considered related to laryngospasm. With the assistance of the predefined anatomy of the airway by ultrasound, we performed an emergent tracheostomy in 9 min, and she regained consciousness gradually without neurological sequela. The patient was managed with broad-spectrum antibiotic therapy, surgical intervention, and admitted to the intensive care unit. She had an uneventful hospital course.

DISCUSSION

Ludwig's angina is a progressive cellulitis with diffuse swelling of sublingual, submandibular, and parapharyngeal spaces and is usually of odontogenic origin.^[3] Ludwig's angina has been a critical health issue and potentially lethal disease. Therapeutic strategies include adequate airway management, aggressive intravenous antibiotics, adequate nutrition support, and surgical intervention (such as incision, drainage, debridement, and skin graft) after an accurate diagnosis. The airway compromise is usually caused by a superiorly displaced tongue, trismus with limited mouth opening, and distorted neck anatomy. Direct laryngoscopy intubation could cause acute airway collapse, thus awake fiberoptic intubation was a better first-line choice for upper airway compromise.^[4] The previous study suggested tracheostomy with local anesthesia as a backup strategy if awake fiberoptic intubation was not practicable, or if intubation attempts had failed.^[5] Correct knowledge of the pathophysiology and anatomy of the neck is required for decisions in maintaining a patent airway in patients with Ludwig's angina. Computed tomography of the neck or focused ultrasound is essential for surveying the details of transmutative structures caused by the inflammatory pathology. As compared with computed tomography, ultrasound is a portable and nonradiant tool with the ability of real-time evaluation for patients.

In the present case, a swollen floor of mouth with a decreased interincisal distance implied trismus, which indicated difficult

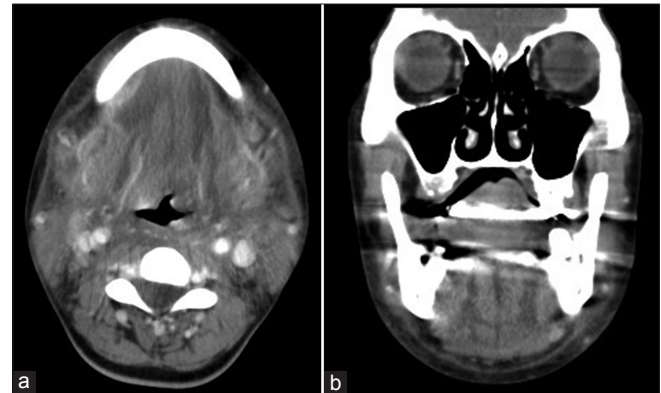

Figure 2: Contrast-enhanced computed tomography of the neck (a) showed diffuse soft-tissue swelling and fatty stranding of the sublingual, submental, and submandibular areas, and the rest of bilateral cervical spaces; (b) swelling of submandibular space resulted in an upper elevation of the tongue and consequently caused pending upper airway obstruction

airway for direct laryngoscopy intubation. Therefore, we chose the strategy of awake fiberoptic intubation with tracheostomy as a backup for safety consideration. Distorted anatomy of her neck also suggested difficulty in applying tracheostomy smoothly. The previous study suggested focused ultrasound, a valid and reliable tool for imaging the oral and oropharyngeal parts of the airway.^[6] Preoperative ultrasound evaluation for airways and identification of the cricothyroid membrane becomes a fundamental skill for anesthetists especially for the patients with Ludwig's angina.^[7-9] Easy bleeding from soft tissues and difficulty in identification of cricothyroid membranes could cause catastrophic situations. Focused ultrasound has also been an excellent tool option for dynamic airway management, which supported to define the tracheal width and distance from the skin to predict tracheostomy tube size and facilitate tracheostomy.^[10] The focused ultrasound could ensure the errorless position of the trachea and avoided the possible accumulation of pus in the neck before and during the procedure of tracheostomy. In the present case, preoperative ultrasound landmarked the level of hyoid bone, vocal cords, cricothyroid membrane, and cricoid cartilages. The minimal depth of trachea from the skin was about 2 cm, which was far beyond normal range and could trap the surgeon during the procedure of tracheostomy. There was no deviation of great vessels such as internal jugular arteries and

veins. We also confirmed no abnormal vascular plexus, abscess, and tumors surrounding the trachea. These also helped us to abridge the operation time and to establish the advanced airway successfully during this procedure. Postoperative ultrasound also revealed no active bleeding and false lumen formation after tracheostomy. Moreover, focused ultrasound could be the alternative tool to assess patients while computed tomography was not available or not suitable (e.g., allergy to the contrast media, and so forth).

Nonetheless, there are still potential limitations associated with focused ultrasound for the emergent airway management in the emergency department. First, the reliability and validity of focused ultrasound depend on the provider's skills and experiences. Second, the probes may compress the airway and worsen symptoms if too much pressure was applied. Third, such procedure needs sufficient operative spaces, equipment, and staffs especially in the crowding emergency settings.

Management of difficult airway for Ludwig's angina is still challenging. Predefined airway anatomy by focus ultrasound, not just by palpation can enhance the surgeons' understanding about distorted airway anatomy including the precise position of the trachea, and assist in emergent tracheostomy implementation more quickly and efficiently in this critical condition.

Declaration of patient consent

The authors certify that they have obtained all appropriate patient consent forms. In the form the patient(s) has/have given his/her/their consent for his/her/their images and other clinical information to be reported in the journal. The patients understand that their names and initials will not be published and due efforts will be made to conceal their identity, but anonymity cannot be guaranteed.

Financial support and sponsorship

Nil.

Conflicts of interest

There are no conflicts of interest.

REFERENCES

1. Candamourty R, Venkatachalam S, Babu MR, Kumar GS. Ludwig's angina-an emergency: A case report with literature review. *J Nat Sci Biol Med* 2012;3:206-8.
2. Pourmand A, Lee D, Davis S, Dorwart K, Shokoohi H. Point-of-care ultrasound utilizations in the emergency airway management: An evidence-based review. *Am J Emerg Med* 2017;35:1202-6.
3. Mathew GC, Ranganathan LK, Gandhi S, Jacob ME, Singh I, Solanki M, *et al.* Odontogenic maxillofacial space infections at a tertiary care center in North India: A five-year retrospective study. *Int J Infect Dis* 2012;16:e296-302.
4. Kremer MJ, Blair T. Ludwig angina: Forewarned is forearmed. *AANA J* 2006;74:445-51.
5. Ovassapian A, Tuncbilek M, Weitzel EK, Joshi CW. Airway management in adult patients with deep neck infections: A case series and review of the literature. *Anesth Analg* 2005;100:585-9.
6. Abdallah FW, Yu E, Cholvisudhi P, Niazi AU, Chin KJ, Abbas S, *et al.* Is ultrasound a valid and reliable imaging modality for airway evaluation? An observational computed tomographic validation study using submandibular scanning of the mouth and oropharynx. *J Ultrasound Med* 2017;36:49-59.
7. Okano H, Uzawa K, Watanabe K, Motoyasu A, Tokumine J, Lefor AK, *et al.* Ultrasound-guided identification of the cricothyroid membrane in a patient with a difficult airway: A case report. *BMC Emerg Med* 2018;18:5.
8. Fulkerson JS, Moore HM, Anderson TS, Lowe RF Jr. Ultrasonography in the preoperative difficult airway assessment. *J Clin Monit Comput* 2017;31:513-30.
9. Osman A, Sum KM. Role of upper airway ultrasound in airway management. *J Intensive Care* 2016;4:52.
10. Garg R, Gupta A. Ultrasound: A promising tool for contemporary airway management. *World J Clin Cases* 2015;3:926-9.